

# Otolaryngology -- Head and Neck Surgery

<http://oto.sagepub.com/>

## Fibrous Incudostapedial Joint in Congenital Aural Atresia

Ashley E. Balaker, Joseph B. Roberson, Jr and Hernan Goldsztein

*Otolaryngology -- Head and Neck Surgery* published online 21 January 2014

DOI: 10.1177/0194599813519745

The online version of this article can be found at:

<http://oto.sagepub.com/content/early/2014/01/21/0194599813519745>

Published by:



<http://www.sagepublications.com>

On behalf of:



AMERICAN ACADEMY OF  
OTOLARYNGOLOGY-  
HEAD AND NECK SURGERY

FOUNDATION

[American Academy of Otolaryngology- Head and Neck Surgery](http://www.aao-hns.org)

Additional services and information for *Otolaryngology -- Head and Neck Surgery* can be found at:

Published online 21 January 2014 in advance of the print journal.

**P<P**

**Email Alerts:** <http://oto.sagepub.com/cgi/alerts>

**Subscriptions:** <http://oto.sagepub.com/subscriptions>

**Reprints:** <http://www.sagepub.com/journalsReprints.nav>


**Permissions:** <http://www.sagepub.com/journalsPermissions.nav>

>> [OnlineFirst Version of Record](#) - Jan 21, 2014

[What is This?](#)

# Fibrous Incudostapedial Joint in Congenital Aural Atresia

Ashley E. Balaker, MD<sup>1</sup>, Joseph B. Roberson, Jr, MD<sup>1</sup>, and Hernan Goldsztein, MD<sup>2</sup>

Otolaryngology—  
 Head and Neck Surgery  
 1–4  
 © American Academy of  
 Otolaryngology—Head and Neck  
 Surgery Foundation 2014  
 Reprints and permission:  
[sagepub.com/journalsPermissions.nav](http://sagepub.com/journalsPermissions.nav)  
 DOI: 10.1177/0194599813519745  
<http://otojournal.org>  


Sponsorships or competing interests that may be relevant to content are disclosed at the end of this article.

## Abstract

**Objectives.** (1) Determine the prevalence of a non-bony or fibrous incudostapedial (IS) joint in the setting of congenital aural atresia. (2) Assess this anomaly's impact on surgical management and associated hearing outcomes.

**Study Design.** Retrospective chart review.

**Setting.** Subspecialty private practice.

**Subjects and Methods.** Operative reports and audiometric data of patients who underwent congenital aural atresia repair by a single surgeon from 2007 to 2011 were reviewed for operative anatomic findings and audiometric outcomes.

**Results.** Two hundred twenty-eight operations on 206 ears were performed. Median age was 5 years old. Fifty-five (26.7%) of these ears had a fibrous IS joint. The severity of this anomaly was graded as mild in 23 ears, moderate in 20 ears, and severe in 12 ears. Mean postoperative pure tone air conduction (PTA2) in the severely fibrous group was 51 compared to 46 in the moderate group ( $P = .03$ ) and 41 in the mild group ( $P = .006$ ). Patients with a fibrous IS joint who underwent successful ossicular chain reconstruction (OCR) had a mean postoperative PTA2 of 30, which was a significantly better outcome than in patients with moderately or severely fibrous IS joints who did not have OCR ( $P < .05$ ).

**Conclusion.** A fibrous IS joint was seen in 27% of patients undergoing repair of congenital aural atresia. The severity of this anomaly has important implications for postoperative hearing results. These findings suggest that ossicular chain reconstruction should be performed in moderately or severely fibrous cases.

## Keywords

aural atresia, incus, stapes, conductive hearing loss, ossicular reconstruction, microtia

Received October 23, 2013; revised December 6, 2013; accepted December 18, 2013.

## Introduction

Congenital aural atresia (CAA) occurs in approximately 1:10,000-20,000 births as a result of the aberrant development of the first and second branchial apparatus.<sup>1</sup> The inner ear's distinct origin from the otocyst makes it less likely to be malformed in cases of CAA.<sup>2</sup> Therefore, the majority of patients with CAA have normal sensorineural hearing but suffer from a maximal conductive hearing loss due to the atretic external auditory canal and anatomic abnormalities of the ossicular chain.<sup>3</sup> Since inner ear function is preserved, surgical atresia repair or bone anchored hearing implants can offer restoration of normal hearing in these patients. The potential hearing outcome from surgical atresia repair is heavily dependent on the existing middle ear anatomy, which has previously inspired the development of several atresia grading scales.<sup>1</sup> These scales are based on temporal bone anatomy present on temporal bone CT prior to surgery. The Jahrsdoerfer grading scale,<sup>4</sup> in our experience, has value in predicting postoperative hearing results, with 80% of patients with a grade of 8 achieving normal hearing thresholds as defined as a speech reception threshold (SRT) less than or equal to 25 dB.

It has been our experience, however, that the incudostapedial (IS) joint is not always visible on CT and therefore difficult to assess preoperatively. Furthermore, even in patients with a visible IS joint on CT scan, intraoperative exam may find a malformed or fibrous IS joint.

To our knowledge there is not previous description of the congenital fibrous anomaly of the incudostapedial joint in the condition of Atresia-Microtia in the existing medical literature, which we have named a fibrous IS joint (FISJ). This malformation of the incudostapedial joint consists of a fibrous scar band in place of the normal bony joint between the incus and stapes (**Figure 1**). At our institution, beginning in 2007, we documented the presence of this anomaly

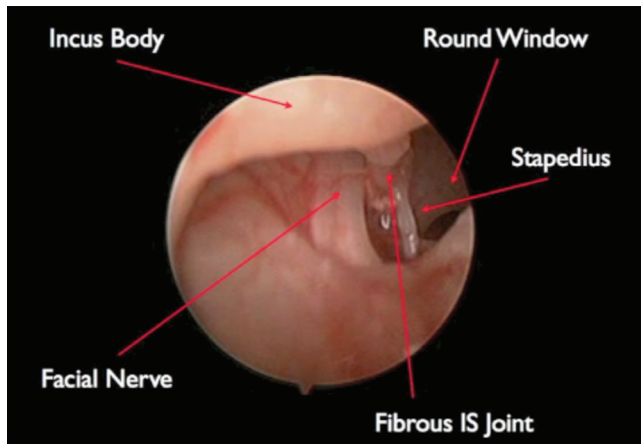
<sup>1</sup>California Ear Institute, Palo Alto, California, USA

<sup>2</sup>California Head and Neck Specialists, San Diego, California, USA

This article was presented at the 2013 AAO-HNSF Annual Meeting & OTO EXPO; September 29-October 3, 2013; Vancouver, British Columbia, Canada.

## Corresponding Author:

Ashley E. Balaker, MD, California Ear Institute, 1900 University Avenue, Suite 101, Palo Alto, CA 94303, USA.  
 Email: [abalaker@calear.com](mailto:abalaker@calear.com)



**Figure 1.** Endoscopic intraoperative photo of severely fibrous incudostapedial joint.

at the time of surgery and also graded its severity as mildly, moderately, or severely fibrous based on palpation of the lateral ossicular mass and the resultant motion of the stapes. In severe cases there is minimal, if any, stapes movement in response to this palpation, despite a mobile stapes footplate.

The objective of this study was to determine the prevalence of this ossicular anomaly in our CAA patients undergoing surgical atresia repair. Furthermore, we sought to determine the impact of a FISJ and its severity on postoperative hearing outcomes. This would allow us to better counsel patients preoperatively and also determine the need for alternative surgical interventions such as ossicular reconstruction at the time of primary repair.

## Materials and Methods

Institutional Review Board exemption status was obtained for this project from the Western Institutional Review Board (Olympia, Washington). All photographs in this article have written consent by the patients or caregiver on file.

We performed a retrospective chart review of all patients undergoing repair of CAA by a single surgeon (JBR) from January 2007 through December 2011. Demographic and medical data were recorded in a password-protected Bento database (FileMaker, Inc, Santa Clara, California) with each patient's evaluation and surgery. This information was de-identified and exported into Excel (Microsoft Corporation, Redmond, Washington) for retrospective review. Inclusion criteria were patients who had a fibrous incudostapedial joint noted on their operative report. The severity of the FISJ had been subjectively graded by surgeon palpation as mild, moderate, or severe at the time of surgery. In all of these cases an anterior approach was used, the native ossicles were left in place, and reconstruction of the tympanic membrane was performed with temporalis fascia and split thickness skin grafting over the reconstructed tympanic membrane and canal walls. Preoperative and postoperative pure tone air conduction (PTA2) scores (average of 500, 1000, 2000, and 3000 Hz) were calculated and analyzed for those patients with adequate audiograms available. All postoperative audiograms were

performed at least 1 month after surgery. Statistical analysis was performed using Excel and StatPlus (AnalystSoft) for *t* test and ANOVA calculations.

Six patients subsequently underwent second stage ossicular reconstruction (OCR) due to poor hearing outcomes, which was defined as a PTA2 equal or greater than 40 dB at 6 months after primary atresia repair and without canal stenosis. These cases were analyzed separately from those undergoing primary atresia repair. All ossicular chain reconstructions were performed using a titanium partial ossicular chain prosthesis, and a cartilage interposition graft was used between the prosthesis and the previously reconstructed tympanic membrane.

## Results

### Prevalence of Fibrous Incudostapedial Joint

Two hundred twenty-eight operations on 206 ears were performed during the study timeframe. Median patient age was 5 years old. Fifty-five (26.7%) of these ears had FISJ. The severity of this anomaly was graded as mild in 23 ears, moderate in 20 ears, and severe in 12 ears. Nineteen ears (35%) were left ears, 36 ears (65%) were right ears. Fourteen ears were from patients with bilateral CAA. Preoperative Jahrsdoefer grading ranged from 5 to 9. Only 1 patient each for grades 5 and 6, 8 patients were graded 7, 36 were graded 8, and 9 were graded 9. Complications in the 55 ears included 1 case of mild high frequency sensorineural hearing loss, 7 salivary fistula that resolved without surgical intervention, and 3 ears with postoperative canal stenosis requiring revision surgery.

### Primary Atresia Repair Hearing Outcomes

Out of the 55 ears identified with FISJ, 41 had sufficient audiometric data for analysis. Of these 41 ears, 15 were graded as mild, 16 as moderate, and 10 as severe. Mean preoperative PTA2 for patients with FISJ undergoing primary atresia repair was 62 dB. The mean postoperative PTA2 for all patients with FISJ without OCR was 46 dB. The mean for timing of postoperative audiograms was 9 months after surgery, with a range of 1 month to 30 months. The mild group had a mean postoperative PTA2 of 41 dB, the moderate group's was 46 dB, and the severe group's was 54 dB ( $P = .02$ ) (**Table 1**).

### Effect of Ossicular Reconstruction on Hearing Outcomes

Six patients out of the original 55 ears subsequently underwent successful second stage ossicular reconstruction with a titanium partial ossicular chain prosthesis. Four of these patients were graded as moderate, 2 as severe. In this group of 6 patients the mean preoperative PTA2 was 57 dB and the mean postoperative PTA2 was 30 dB. To assess the potential benefit of ossicular reconstruction we compared the mean postoperative PTA2 in the reconstructed patients with the mean postoperative PTA2 in each of the FISJ severity groups. Overall, the mean postoperative PTA2 for

**Table 1.** Mean hearing outcomes in patients with fibrous incudostapedial joint.

	Ears	Preoperative PTA2	Postoperative PTA2
All FISJ	41	60 dB ( $\pm 9$ )	46 dB ( $\pm 12$ )
Mild	15	59 dB ( $\pm 10$ )	41 dB ( $\pm 14$ )
Moderate	16	60 dB ( $\pm 9$ )	46 dB ( $\pm 10$ )
Severe	10	62 dB ( $\pm 6$ )	54 dB ( $\pm 9$ )
Second stage OCR	6	58 dB ( $\pm 14$ )	30 dB ( $\pm 10$ )
Moderate	4	55 dB ( $\pm 16$ )	28 dB ( $\pm 10$ )
Severe	2	52 dB ( $\pm 2$ )	35 dB ( $\pm 0$ )

Abbreviations: PTA2, postoperative pure tone air conduction; FISJ, fibrous incudostapedial joint; OCR, ossicular chain reconstruction.

the entire FISJ group without OCR was significantly worse than the mean postoperative PTA2 for the group that underwent OCR ( $P = .01$ ). The mean postoperative PTA2 was significantly better in patients who underwent OCR when compared to the moderate FISJ group ( $P = .01$ ) and the severe FISJ group ( $P = .001$ ). When compared to the mild group, the difference in mean postoperative PTA2 was not statistically significant ( $P = .09$ ).

## Discussion

Surgical CAA repair continues to be one of the most challenging otologic surgeries. Advances in surgical technique have led to improved hearing outcomes and fewer complications when performed by an experienced surgeon.<sup>5,6</sup> However, the patient's anatomy continues to be one of the most significant determinants of postoperative success.

Furthermore, with the advent of bone anchored hearing devices, which offer excellent and predictable hearing results in patients with CAA, preoperative selection and counseling of patients has become even more essential.

Our data revealed a relatively high prevalence of FISJ in patients with CAA undergoing surgical repair, with 27% of these patients having FISJ. Other studies in the literature have mentioned malformations of the ossicular chain and discontinuity of the incudostapedial joint in CAA.<sup>7</sup> However, the effect of this specific anomaly of the ossicular chain has not previously been evaluated or discussed.

Much of the literature regarding surgical atresia repair focuses on prevention of canal restenosis, as this has historically been the most common long-term complication. However, even with a well-healed and patent canal, our patients with FISJ had poorer hearing outcomes. The mean PTA2 for our patients with FISJ was 46 dB. We compared this to our own previously published data in patients undergoing atresia repair prior to microtia reconstruction, in which case patients with J score of 8 to 10 had a postoperative PTA2 of 28, and those with a J score of 7 or less had a postoperative PTA2 of 42.<sup>8</sup>

In Dobratz et al,<sup>7</sup> they concluded that patients undergoing atresia repair who are able to keep their native ossicles have better long-term hearing outcomes compared to those requiring OCR. We also favor utilizing the native ossicular chain whenever possible. However, our data

showed that in cases of moderate or severely fibrous IS joints, OCR offered a better outcome than the native ossicles achieved. Mildly fibrous cases also had worse outcomes than those who had OCR; however, this difference was not statistically significant. In select cases with mild FISJ, OCR may still be necessary as a second stage revision.

Preoperative Jahrsdoerfer grading did not correlate with the severity of FISJ. This may be a limitation of the grading system, since it is not possible to adequately assess whether the IS joint is fibrous or not on temporal bone CT.

All of our cases in this report had OCR performed as second stage operations. In our current practice we have begun performing OCR on moderate and severe FISJ cases at the time of primary atresia repair based on this data. We are interested to determine if these patients have outcomes similar to those undergoing OCR at a second stage or if the OCR during primary repair proves to be less reliable. In mild cases we currently defer to the postoperative audiogram to determine the need for second stage OCR.

Our study has several inherent limitations. Due to the nature of our practice many patients travel from foreign countries and postoperative audiologic data was not always available or reliable, and there was a good deal of variation in the timing of postoperative audiologic testing. Furthermore, postoperative care of the canal was often performed by other physicians and therefore could not be standardized. Our results show that there were a significant number of patients who could have benefited from revision surgery for OCR; however, only 6 patients from our study have undergone OCR. A larger sample size in this population would have offered better statistical analysis. The small size of this group is in part due to the travel and expense required for international patients to undergo a second stage surgery. This problem of patients not undergoing recommended OCR was one of the motivating factors for this study, as we would like to do everything possible at the primary repair to maximize postoperative hearing outcomes. Lastly, the grading of the FISJ was made qualitatively, as there is no accessible method to quantitatively grade the severity of the fibrous union. We attempted to control for this by having all grading done by the same surgeon (JBR). We based our qualitative grading on the movement of the stapes upon palpation of the lenticular process of the incus. No stapes movement was graded as severe, and these IS joints generally

only consisted of a thin scar band. Minimal movement was graded as moderate and the IS joint was visibly fibrous but only somewhat thinned. Normal movement of the stapes was graded as mild, and while these joints appeared fibrous rather than bony, they were not thinned.

## Conclusion

Patients with CAA undergoing surgical atresia repair should be counseled preoperatively regarding the possibility of a FISJ. Our data showed a high prevalence of FISJ in CAA patients (27%). Preoperative CT findings do not demonstrate the presence of a FISJ. Based on our analysis of post-operative hearing outcomes, we recommend ossicular chain reconstruction for patients with moderate or severe FISJ either at the time of primary atresia repair or as a second stage surgery in order to achieve the best possible hearing outcome.

## Author Contributions

**Ashley E. Balaker**, conception of research concept, gathering and analysis of data, drafting and editing of manuscript, presentation of data at national meeting, final approval of manuscript; **Joseph B. Roberson, Jr**, conception of research concept, gathering and analysis of data, editing of manuscript, final approval of manuscript; **Hernan Goldshtein**, conception of research concept, gathering and analysis of data, editing of manuscript, final approval of manuscript.

## Disclosures

**Competing interests:** Joseph B. Roberson, Jr, Acclarent, advisory board; Autonomic Technologies Inc., consultant; Vigilo Networks, employee, equity owner; Lumenis, consultant; Kurz, consultant;

The Doctor's Company, advisory board; Inspire, consultant, study support.

**Sponsorships:** None.

**Funding source:** None.

## References

1. De la Cruz A, Teufert K. Congenital malformation of the external auditory canal and middle ear. In: Brackmann D, Shelton C, Arriaga M, eds. *Otologic Surgery*. 3rd ed. Philadelphia, PA: Saunders; 2010:55-72.
2. Gulya AJ. Developmental anatomy of the temporal bone and skull base. In: Gulya AJ, Minor LB, Poe DS, eds. *Surgery of the Ear*. 6th ed. Beijing, P.R. China: People's Medical Publishing House; 2010:3-27.
3. Vrabc JT, Lin JW. Inner ear anomalies in congenital aural atresia. *Otol Neurotol*. 2010;31:1421-1426.
4. Jahrsdoerfer RA, Yeakley JW, Aguilar EA, et al. Grading system for the selection of patients with congenital aural atresia. *Am J Otol*. 1992;13:6-12.
5. Teufert K, De la Cruz A. Advances in congenital aural atresia surgery. *Otolaryngol Head Neck Surg*. 2004;131:263-270.
6. Patel N, Shelton C. The surgical learning curve in aural atresia surgery. *Laryngoscope*. 2007;117:67-73.
7. Dobratz EJ, Rastogi A, Jahrsdoerfer RA, Kesser BW. To POP or not: ossiculoplasty in congenital aural atresia surgery. *Laryngoscope*. 2008;118:1452-1457.
8. Roberson JB, Reinisch JF, Colen TY, Lewin S. Atresia repair before microtia reconstruction: comparison of early with standard surgical timing. *Otol Neurotol*. 2009;30:771-776.